



## Mycobacteriosis in Fish<sup>1</sup>

Ruth Francis-Floyd, DVM, MS, Dipl ACZM, and Roy Yanong, VMD<sup>2</sup>

### Introduction

Mycobacteriosis in fish is a disease caused by certain bacterial species within the genus *Mycobacterium*. There are many different species of *Mycobacterium* that cause diseases in animals. Some of these cause important diseases in humans. However, those species that cause Mycobacteriosis in fish are referred to as non-tuberculous mycobacteria and do not cause major disease in normal, healthy people.

Non-tuberculous mycobacteria are relatively common environmental bacteria. This means that they can live in the aquatic environment and do not require the presence of fish or fish tissue to survive. They have been isolated from drinking water supplies, swimming pools, coastal waters, and aquaculture facilities.

Mycobacteriosis is a disease of concern in fish for several reasons. First, it causes a chronic wasting condition with continuous low, to moderate, level mortality within the affected population, and can result in significant financial loss to fish culturists. Secondly, the disease is considered non-treatable once established in the fish host. Finally, *Mycobacterium*-infected fish do have the potential to cause disease in humans.

### Species of Mycobacteria that Infect Fish

The genus *Mycobacterium* contains many species of bacteria that cause disease in mammals, birds and reptiles, as well as fish. Three species

believed to account for most incidences of mycobacterial disease in fish are *M. marinum*, *M. fortuitum*, and *M. chelonae*. Of these, *M. marinum* has been reported in fish from both freshwater and marine tropical waters, and *M. fortuitum* in fish from tropical or temperate waters. *M. chelonae* has been associated with disease in hatchery-reared Pacific salmon.

### Environmental Conditions Favoring Mycobacteria

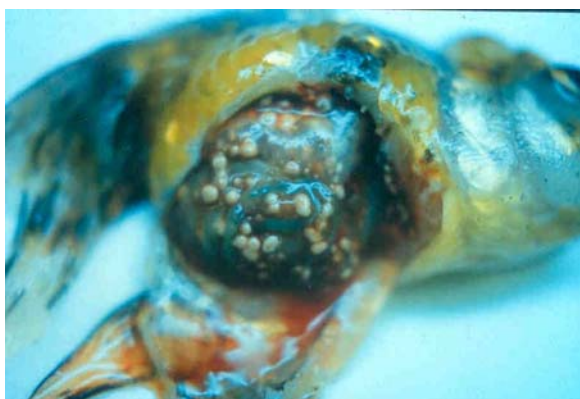
Many of the organisms in this group occur naturally in the aquatic environment. One report compared the prevalence of selected species of non-tuberculous mycobacteria in two different aquatic environments, acidic (boggy) swamps and upland lakes. The investigators found a much higher prevalence of mycobacteria in swamps, and correlated the increased number of organisms with environmental conditions including low levels of dissolved oxygen, low pH, high organic loads, and warm water. These conditions are similar to those commonly encountered in aquaculture systems. Another investigation associated an increased prevalence of non-tuberculous mycobacteria with low salinity, another condition found in freshwater aquaculture systems. Trace amounts of certain minerals, particularly zinc and iron, have also been correlated with increased numbers of environmental mycobacteria.

<sup>1</sup> This document is Fact Sheet VM-96, one of a series from the Veterinary Medicine-Large Animal Clinical Sciences Department, Florida Cooperative Extension Service, Institute of Food and Agricultural Sciences, University of Florida. First published: January 1, 1999. Reviewed: August 2002. Please visit the EDIS Web Site at <http://edis.ifas.ufl.edu>.

<sup>2</sup> Ruth Francis-Floyd, DVM, Extension Veterinarian for Aquaculture and Professor, Department of Large Animal Clinical Sciences, Florida Cooperative Extension Service, Institute of Food and Agricultural Sciences, University of Florida, Gainesville, FL 32611 and Roy P.E. Yanong, Assistant Professor, Tropical Aquaculture Laboratory, Department of Fisheries and Aquatic Sciences, Florida Cooperative Extension Service, Institute of Food and Agricultural Sciences, University of Florida, Ruskin, FL 33570-3434.

## Signs of Mycobacteriosis in Fish

Because of the slow progression of the disease, younger fish infected with mycobacteriosis show no external signs. As fish age or are stressed, the infection becomes more serious. A chronic progressive disease develops that may be characterized by emaciation, inflammation of the skin, exophthalmia (“pop-eye”), open lesions, or ulceration. Fish may become sluggish and bloated, refuse to eat, and develop fin and tail rot as well as scale loss. Internally, gray-white granulomas (nodules) develop in the liver, kidney, spleen, heart, and muscles (Figure 1). When the nodules develop in the organs, edema (excess fluid accumulation) may develop, as well as peritonitis (inflammation of the body cavity). If infection spreads to the skeletal system, deformities such as a bent spine may be noticed. Eventually, infected fish succumb and die.

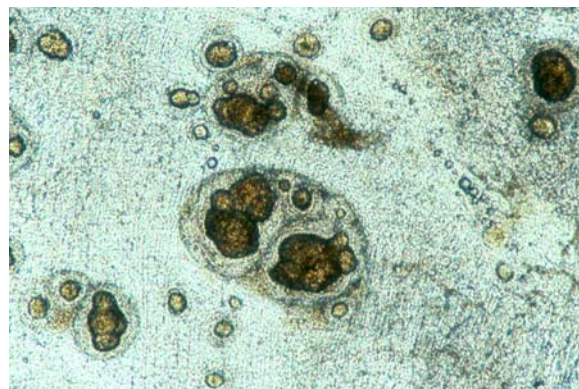


**Figure 1.** Granulomas (nodules) are readily visible on multiple organs in the abdominal cavity during necropsy. The disease in this fish was very advanced.

## Diagnosis

A presumptive diagnosis of mycobacteriosis can be based on the presence of typical granulomas, which will be seen at necropsy (Figure 1). The fish shown in Figure 1 has a very advanced infection. However, it is possible to see granulomas using a light microscope by making wet mounts of organ tissue (Figure 2). For this reason, a wet mount should be made of liver, spleen, and kidney tissue as part of a routine necropsy. Granulomas will also often be present on skin ulcerations. If granulomas are seen, an acid-fast stain should be performed immediately on suspect tissue. In the laboratory, granulomatous material is smeared onto a slide, dried, heat-fixed, and stained with Kinyoun or

Ziehl-Nielsen stain to confirm the presence of acid-fast bacteria. A positive acid-fast stain reveals red to pink rod-shaped bacteria against a light green background. The bacteria will appear in the center of, or surrounding suspect lesions. A positive acid-fast stain very strongly supports the diagnosis. A negative acid-fast stain (no red or pink rods seen) suggests another cause for the granulomas, such as parasites or fungus.



**Figure 2.** Granulomas in an unstained wet mount. When this tissue change is observed, an acid-fast stain is indicated.

Fish suspected of being infected with mycobacteria should be submitted to a diagnostic laboratory to confirm the infection, and, if possible, to culture and identify the causative agent. Acid-stains will be performed on fresh tissue as described above, in addition to acid-fast stains of histopathological samples. Crushed granulomas are also streaked onto Lowenstein-Jensen or Dorset media, specialized growth media for mycobacteria, where growth can take up to 28 days. Confirmation of the diagnosis by culture of the organism is desirable, although no growth does not necessarily rule out mycobacteria, especially if acid-fast organisms are present.

## Mycobacteria-infected Fish Populations

Mycobacteriosis causes a chronic to subacute disease in many different species of fish, including those that inhabit fresh, brackish or marine environments. When present in a population, infection rates can vary from 10% to 100%. Unfortunately, there is no non-lethal method available to identify infected individuals, especially

those in early to mid stages of disease. Fish with late-stage disease often develop ulcerations and other external lesions that may have some diagnostic value. Therefore, if one fish in a population is diagnosed with the condition, then the entire population must be considered exposed and potentially infected. Methods for detection of infected individuals have yet to be developed. In addition, factors that promote the establishment of mycobacteria within a given aquaculture system also need to be identified to decrease chance of exposure. Finally, factors that promote infection need to be determined to avoid development of disease in exposed individuals.

Unlike most other bacterial diseases, there is no cure for mycobacteriosis. The infection will smolder in infected fish, resulting in chronic health problems and mortality in the population. This situation is not consistent with maintenance of “Good Management Practices” for aquaculturists. Efforts to eliminate infection in affected populations with prolonged use of antibiotics have not been successful medically and are prohibitively expensive.

### **Transmission**

Epidemiology, which is the study of the prevalence and spread of the disease in a population, is poorly understood for mycobacteriosis in fish. The most common method of transmission is assumed to be ingestion of infected material. This can occur if fish are fed fish products that have not been thoroughly cooked, or if an infected fish dies and is consumed by other fish in the population. Fish may also contract the infection through open wounds in their skin if the number of bacteria in the environment is high enough or if the fish has a poorly operating immune system. It is suspected that vertical transmission (transmission from parent to offspring) may occur through egg or sperm products. If this is the case, maintenance of mycobacteria-infected broodstock would be totally unacceptable for fish culturists.

### **Human Health Concerns**

Although transmission from infected fish to humans is rare, it is important to be aware of the potential occurrence.

*Mycobacterium* spp. that cause disease in fish occasionally cause a skin infection in people that is referred to as “fish handler's disease” or “fish tank granuloma.” In most cases, the infected individual has been in contact with high numbers of infective particles, with a break in the skin at the original infection site. The infection is characterized by pustules that resemble a rash and occur on body parts exposed to contaminated water or fish, generally the hands, arms, or legs. The pustules exude a thick white to yellow fluid. In healthy individuals the disease is usually self-limiting and often heals on its own. However, there are reported cases of more severe localized infections resulting from deep penetrating wounds in fishermen. Also, immunologically compromised individuals are at greater risk of developing systemic infections. Regardless, anyone who suspects that he or she may have contracted mycobacteriosis from fish or an aquarium should see their physician.

### **Management**

Mycobacterial infections of fish should be considered non-treatable. Therefore, it is best to destroy infected stocks and thoroughly disinfect facilities before restocking. Following depopulation, the entire system, especially the filter bed, must be thoroughly disinfected with a mycobactericidal product (see below). In addition, all equipment that has been in contact with the infected fish should be disinfected. Gloves should be worn when handling infected fish or cleaning contaminated tanks or other equipment. Hands should be washed thoroughly afterwards with 70% isopropyl alcohol and a bactericidal soap. Under no circumstances should fish from an infected population be sold, moved or given away.

Management of mycobacteriosis for large aquatic exhibits at zoos or public aquaria may differ somewhat from management at production facilities. Because display exhibits have often been in continuous operation for several years and may have large numbers of fish of different species, there is a greater probability of low level infection. If one or two fish are found to have mycobacterial infections, a fish veterinarian should be consulted immediately. Random or targeted sampling of other fish in the same exhibit should be considered to assess approximate prevalence of the disease in

the group. Depending upon this prevalence and the advice of a knowledgeable veterinarian, further action may or may not be warranted. At best, continuous monitoring of diseased fish for presence of mycobacteriosis should be undertaken. At worst, as recommended in production facilities, the entire exhibit may require depopulation and thorough disinfection with chlorine and isopropyl alcohol.

### **Disinfection Protocol**

Mycobacteria are resistant to many commonly used bactericidal agents at standard dosage rates, including chlorine bleach and quaternary ammonium compounds. As much as 10,000 ppm chlorine has been reported necessary to kill mycobacteria. Mycobacteria are sensitive to 60-85% alcohol. In addition, there are special products marketed specifically to decontaminate mycobacteria-infected surfaces. However, if these are used, efforts must be made to remove all residues of disinfectant.

### **Summary**

Fish mycobacteriosis is a chronic and debilitating disease that can affect marine and freshwater fish. Little is known about the factors that influence the frequency and distribution of this pathogenic organism. Infected fish are a primary reservoir of infection, although non-tuberculous mycobacteria can be found in the environment. Mycobacteriosis can be suspected when gray-white nodules (granulomas) are seen on internal organs, either grossly or on wet mounts using a light microscope. Disease diagnosis is confirmed by staining suspect tissue with an acid-fast stain. There is no treatment for fish infected with mycobacteria, so depopulation of an infected group is strongly recommended. Contaminated water and equipment should be thoroughly disinfected. People who may be exposed to infected material should wear gloves and wash thoroughly with 70% isopropyl alcohol and an antibacterial soap. Immuno-compromised individuals should be prevented from having direct contact with mycobacteria-infected material.